

PROSTATE MRI, PI-RADS AND THE WRH-OUELLETTE CAMPUS EXPERIENCE


Igor Gaisinsky, MD, FRCPC

A series of several parallel white lines of varying thicknesses, slanted diagonally from the bottom right towards the top right, set against a blue gradient background.

I HAVE NO DISCLOSURES



LEARNING OBJECTIVES:

1. To review appropriate indications for MRI of the prostate in Ontario.
 2. To review the MRI criteria for clinically significant prostate cancer as per PI-RADS version 2.
 3. To review some locally performed illustrative prostate MRI cases to highlight both pitfalls and utility of prostate MRI.
- 
- A decorative graphic consisting of several parallel white lines of varying lengths and thicknesses, arranged in a diagonal pattern from the bottom right towards the top right of the slide.

INDICATIONS FOR PROSTATE MRI IN ONTARIO

1. Rising PSA with a negative biopsy – very useful to find the anterior or small lesions that may be missed on random systemic TRUS biopsy
2. Active surveillance of low grade prostate cancer
3. Pre-operative staging
4. ?clarification of non-specific prostatic findings from other imaging

Note: CCO recommendations as of 2015 do not recommend mpMRI in the biopsy naive patient with increased risk of prostate CA (rising PSA) – evidence quality was poor to moderate, detection rates from mpMRI followed by targeted biopsy were not consistently higher than systemic biopsy (there has been literature recently that disputes this but topic remains unsettled), ? Limitation of resources – remains controversial topic and further data is needed

PROSTATE MRI BACKGROUND:

-utility of MRI in prostate cancer diagnosis has been known since the late 1980s when several studies showed that prostate cancer in the peripheral zone shows low T2 signal.

-however, low T2 signal in the peripheral zone was found to be of relatively low sensitivity and specificity, as some tumours were isointense to normal prostate and there were many non-malignant causes of peripheral zone low T2 signal (ie. Hemorrhage, prostatitis, scar,...)

-standard T1 weighted imaging was found to be helpful for post- bx hemorrhage detection, but not for prostate Ca

-in the 2000s, diffusion-weighted imaging was introduced to prostate MR imaging, and significantly increased the sensitivity for prostate cancer detection, particularly in the peripheral zone.

PROSTATE MRI BACKGROUND:

-at a similar time period, several other techniques to aid in detection of clinically significant prostate cancer were being developed, including dynamic contrast enhanced MR imaging and MR spectroscopy

-with the newer techniques, the standard for multiparametric prostate MR imaging was initially felt to be 1.5 Tesla MRI with an endorectal coil or 3 Tesla (with or without an endorectal coil) - it has since been recognized that good quality prostate MR imaging can be achieved with a 1.5 Tesla MRI without an endorectal coil

-in response to emerging role of MRI in prostate cancer, the multiple MR techniques available, and the variability in performance, interpretation and reporting, the ESUR developed version 1 of PI-RADS (Prostate Imaging Reporting and Data System) in 2012

PI-RADS

-in response to PI-RADS v.1, and to achieve more global standardization and acceptance, multiple groups including ACR and ESUR established a steering committee which subsequently (2015) put out the current PI-RADS version 2 document which we currently use

-sets the current standard for prostate MRI image acquisition, interpretation, and reporting in the treatment naïve prostate

PI-RADS V2: TECHNIQUE

- the PI-RADS v2 document stipulates using T2, DWI (diffusion weighted imaging), and DCE (dynamic contrast enhanced) imaging for prostate MRI evaluation
- many groups, including ours, have modified this somewhat to include DCE only in selected cases
- although 3 Tesla MRI is stated to be preferable, due to better spatial/temporal resolution and improved DWI image quality, 1.5 T MRI is felt to be acceptable when imaging parameters are fully optimized for diagnostic work (not recommended for MR guided or MR/US fusion guided biopsy/procedures)

PI-RADS V2:TECHNIQUE

Current prostate MRI protocol at WRH-Ouellette campus includes:

- Sagittal, Coronal, and axial high resolution T2-weighted images
- Axial T1 (small field of view prostate for hemorrhage/ calcification and larger FOV of whole pelvis for lymph nodes)
- Diffusion weighted imaging (DWI), including “high B value” DWI with B=1400
- contrast enhanced imaging may be added for staging of known prostate cancer or in select situations of equivocal peripheral zone findings

- ▶ PI-RADS™ v2 Assessment Categories
- ▶ PIRADS 1 – Very low (clinically significant cancer is highly unlikely to be present)
- ▶ PIRADS 2 – Low (clinically significant cancer is unlikely to be present)
- ▶ PIRADS 3 – Intermediate (the presence of clinically significant cancer is equivocal)
- ▶ PIRADS 4 – High (clinically significant cancer is likely to be present)
- ▶ PIRADS 5 – Very high (clinically significant cancer is highly likely to be present)

PI-RADS V2 : REPORTING

-5 point scale based on probability that a combination on mpMRI findings will correlate with clinically significant cancer

-PIRADS v2 defines clinically significant cancer as Gleason score greater than or equal to 7 (including 3+4 with prominent but not predominant Gleason 4 component), and/or volume greater than or equal to 0.5 cc, and/or extra prostatic extension

PI-RADS Assessment

Peripheral Zone (PZ)

DWI	T2W	DCE	PI-RADS
1	Any*	Any	1
2	Any	Any	2
3	Any	-	3
		+	4
4	Any	Any	4
5	Any	Any	5

* "Any" indicates 1-5

PERIPHERAL ZONE

- ▶-for the peripheral zone, DWI is the dominant sequence
- ▶-note that T2 does not contribute to the PI-RADS categorization for peripheral zone lesions
- ▶DCE is only helpful for equivocal PI-RADS 3 lesions, a +ve DCE will upgrade the lesions to PI-RADS 4

Transition Zone (TZ)

T ₂ W	DWI	DCE	PI-RADS
1	Any*	Any	1
2	Any	Any	2
3	≤4	Any	3
	5	Any	4
4	Any	Any	4
5	Any	Any	5

* "Any" indicates 1-5

TRANSITIONAL ZONE

- ▶-note that T2 is the dominant sequence for the transitional zone
- ▶DCE makes no contribution for transitional zone
- ▶Only a DWI score of 5 can change an equivocal transitional zone lesion to PI-RADS 4

-RADS Assessment for T2W

Score	Peripheral Zone (PZ)
1	Uniform hyperintense signal intensity (normal)
2	Linear or wedge-shaped hypointensity or diffuse mild hypointensity, usually indistinct margin
3	Heterogeneous signal intensity or non-circumscribed, rounded, moderate hypointensity Includes others that do not qualify as 2, 4, or 5
4	Circumscribed, homogenous moderate hypointense focus/mass confined to prostate and <1.5 cm in greatest dimension
5	Same as 4 but ≥ 1.5 cm in greatest dimension or definite extraprostatic extension/invasive behavior

Score	Transition Zone (TZ)
1	Homogeneous intermediate signal intensity (normal)
2	Circumscribed hypointense or heterogeneous encapsulated nodule(s) (BPH)
3	Heterogeneous signal intensity with obscured margins Includes others that do not qualify as 2, 4, or 5
4	Lenticular or non-circumscribed, homogeneous, moderately hypointense, and <1.5 cm in greatest dimension
5	Same as 4, but ≥ 1.5 cm in greatest dimension or definite extraprostatic extension/invasive behavior

► Diffusion Weighted Imaging (DWI)

Score	Peripheral Zone (PZ) or Transition Zone (TZ)
1	No abnormality (i.e., normal) on ADC and high b-value DWI
2	Indistinct hypointense on ADC
3	Focal mildly/moderately hypointense on ADC and isointense/mildly hyperintense on high b-value DWI.
4	Focal markedly hypointense on ADC and markedly hyperintense on high b-value DWI; <1.5cm in greatest dimension
5	Same as 4 but ≥ 1.5 cm in greatest dimension or definite extraprostatic extension/invasive behavior

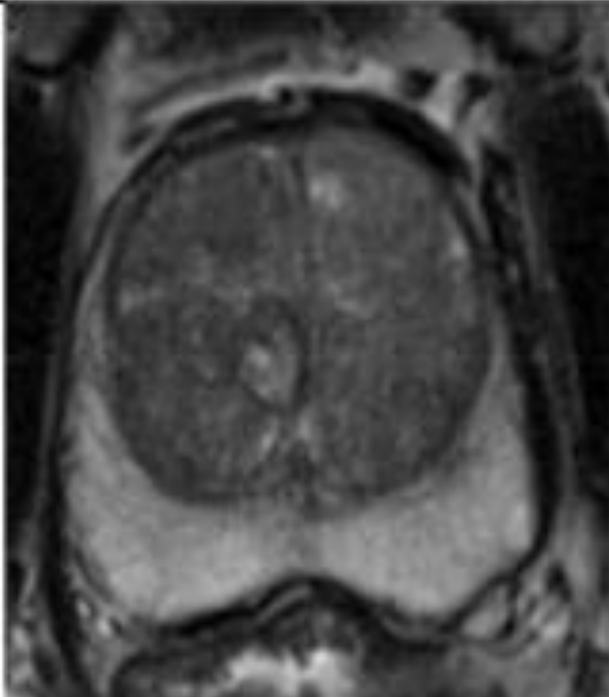
DYNAMIC CONTRAST ENHANCED (DCE) IMAGING

PI-RADS Assessment for DCE

Score	Peripheral Zone (PZ) or Transition Zone (TZ)
(-)	no early enhancement, or diffuse enhancement not corresponding to a focal finding on T2W and/or DWI or focal enhancement corresponding to a lesion demonstrating features of BPH on T2WI
(+)	focal, and; earlier than or contemporaneously with enhancement of adjacent normal prostatic tissues, and; corresponds to suspicious finding on T2W and/or DWI

PI-RADS ASSESSMENT FOR PERIPHERAL ZONE ON T2

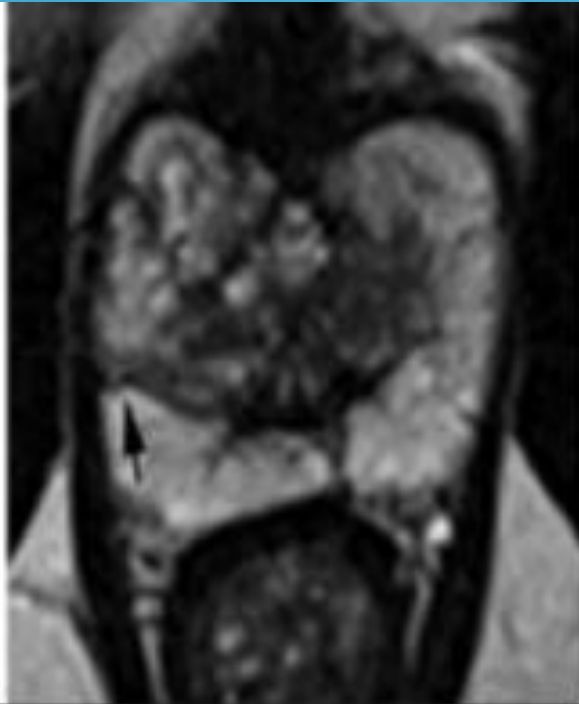1



Uniform hyperintense signal intensity (normal).

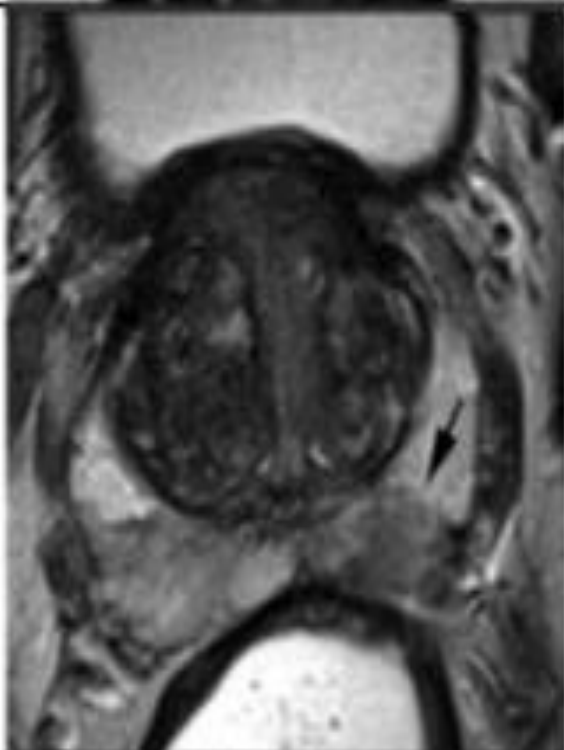
PI-RADS ASSESSMENT FOR PERIPHERAL ZONE ON T2

2



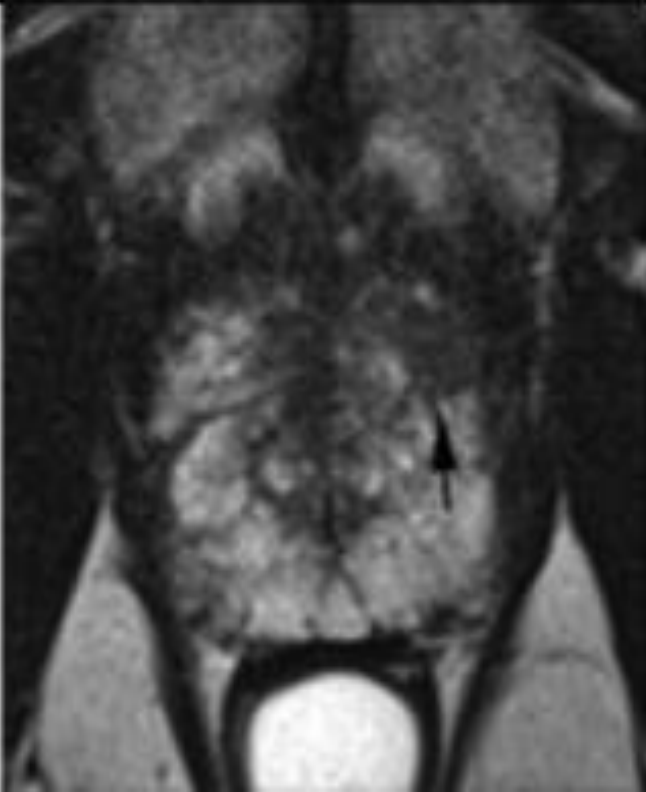
Linear (*arrow*), wedge-shaped, or diffuse mild hypointensity, usually indistinct margin.

PI-RADS ASSESSMENT FOR PERIPHERAL ZONE ON T2

3		Heterogeneous signal intensity or non-circumscribed, rounded, moderate hypointensity (<i>arrow</i>).
---	---	--

PI-RADS ASSESSMENT FOR PERIPHERAL ZONE ON T2

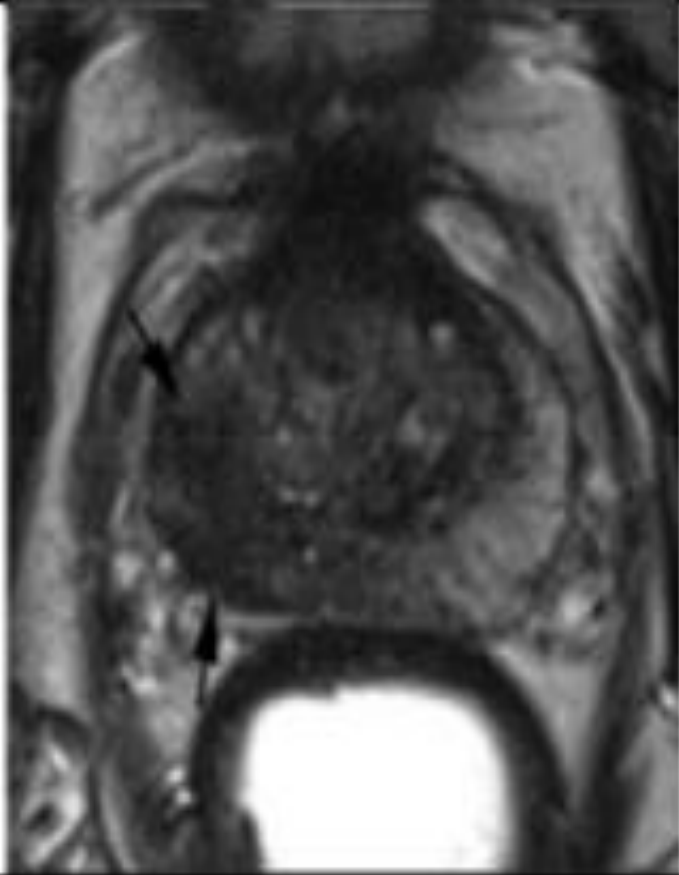
4



Circumscribed, homogenous moderate hypointense focus/mass confined to prostate and <1.5 cm in greatest dimension (*arrow*).

PI-RADS ASSESSMENT FOR PERIPHERAL ZONE ON T2

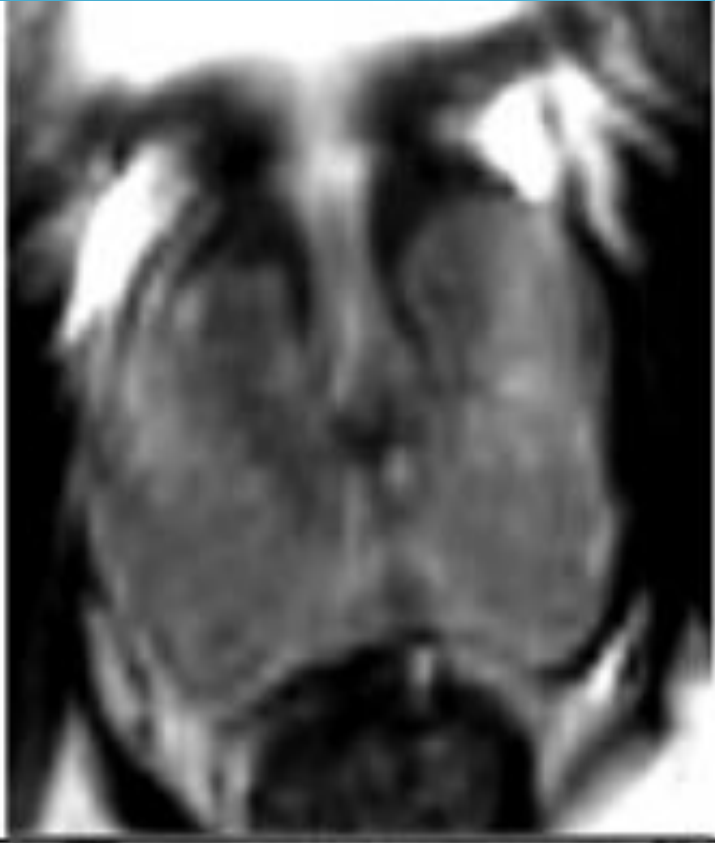5



Same as 4 but ≥ 1.5 cm in greatest dimension (*arrows*) or definite extraprostatic extension/invasive behavior.

PI-RADS ASSESSMENT FOR TRANSITIONAL ZONE ON T2

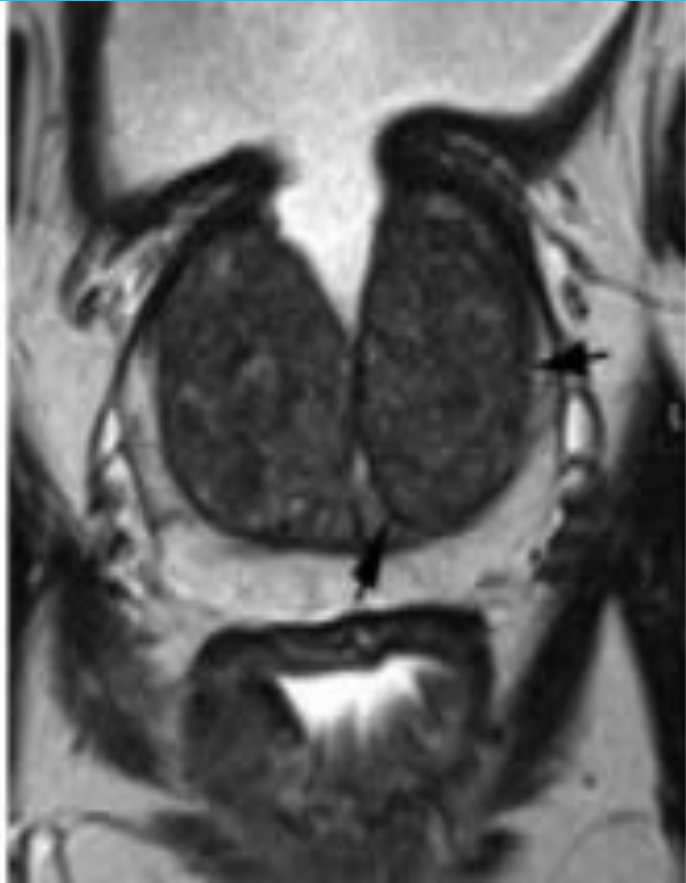1



Homogeneous intermediate signal intensity (normal).

PI-RADS ASSESSMENT FOR TRANSITIONAL ZONE ON T2

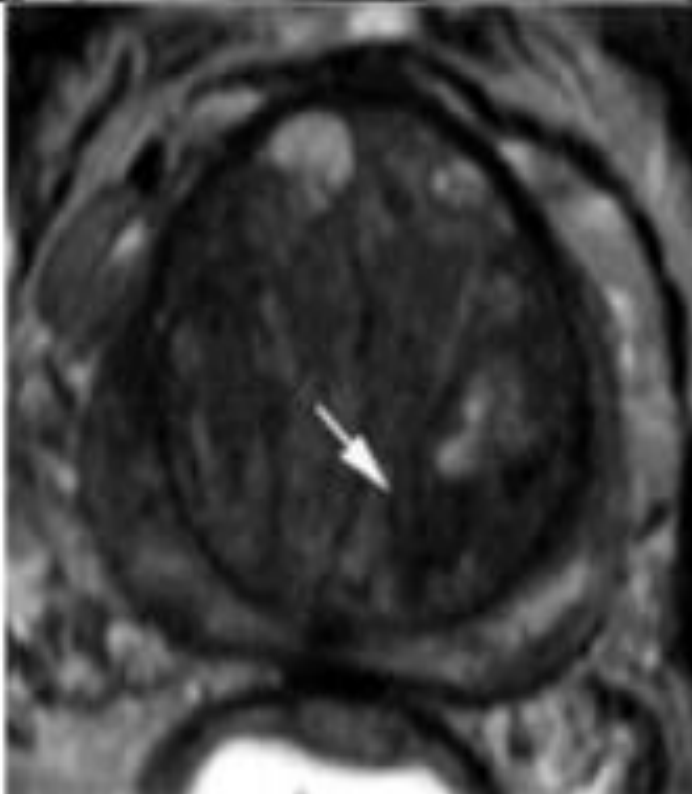
2



Circumscribed (*arrows*) hypointense or heterogeneous encapsulated nodule(s) (BPH).

PI-RADS ASSESSMENT FOR TRANSITIONAL ZONE ON T2

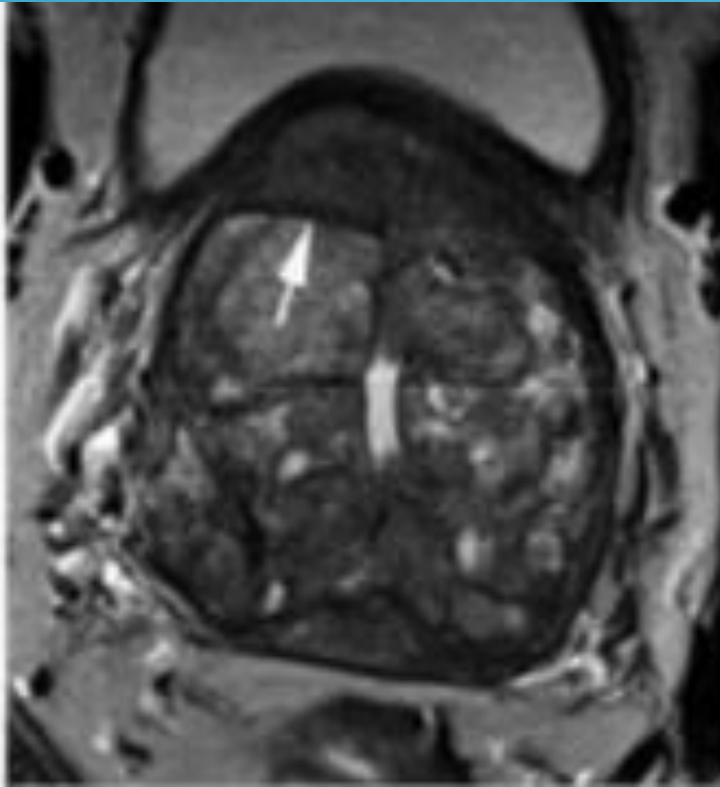
3



Heterogeneous signal intensity with obscured margins (*arrow*). Includes others that do not qualify as 2, 4, or 5.

PI-RADS ASSESSMENT FOR TRANSITIONAL ZONE ON T2

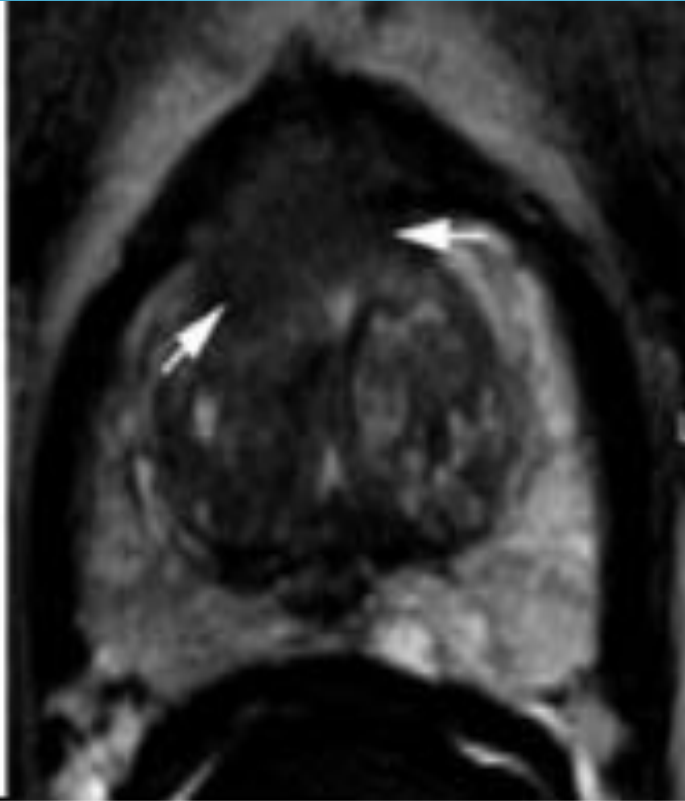
4



Lenticular (*arrow*) or non-circumscribed, homogeneous, moderately hypointense, and <1.5 cm in greatest dimension.

PI-RADS ASSESSMENT FOR TRANSITIONAL ZONE ON T2

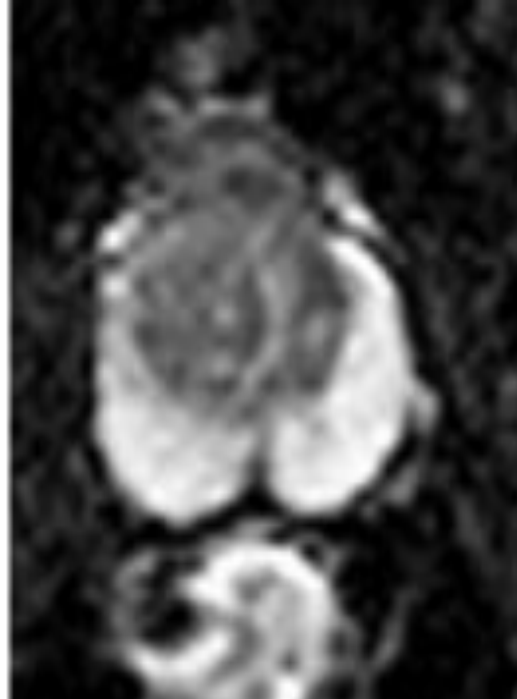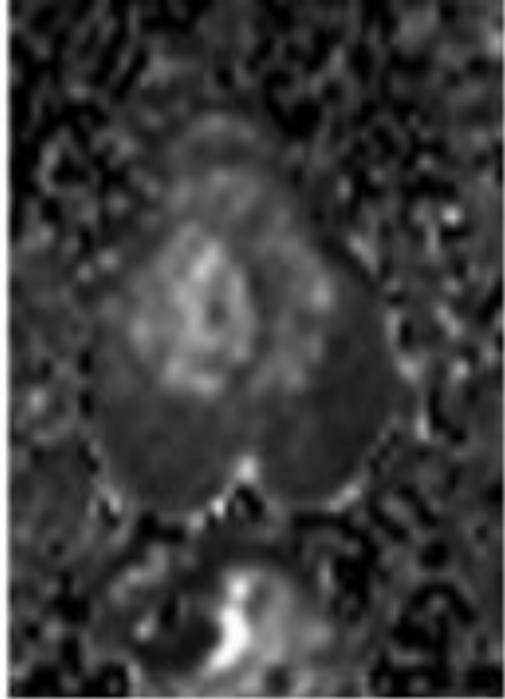
5



Same as 4, but ≥ 1.5 cm in greatest dimension (*arrows*) or definite extraprostatic extension/invasive behavior.

PI-RADS ASSESSMENT FOR PERIPHERAL ZONE ON DWI

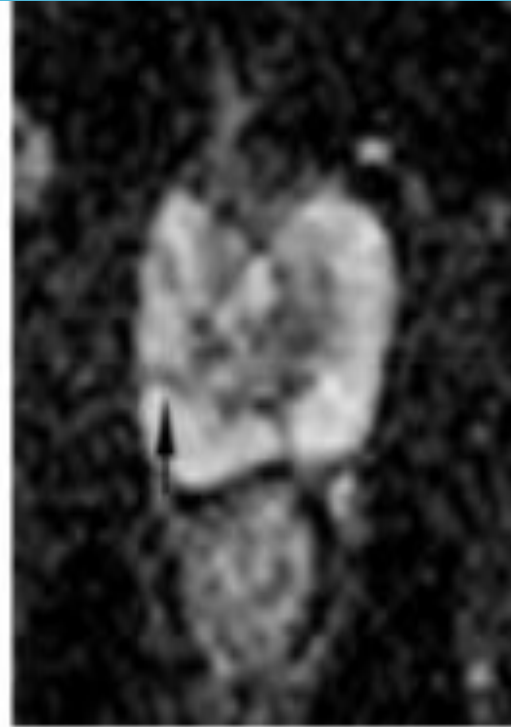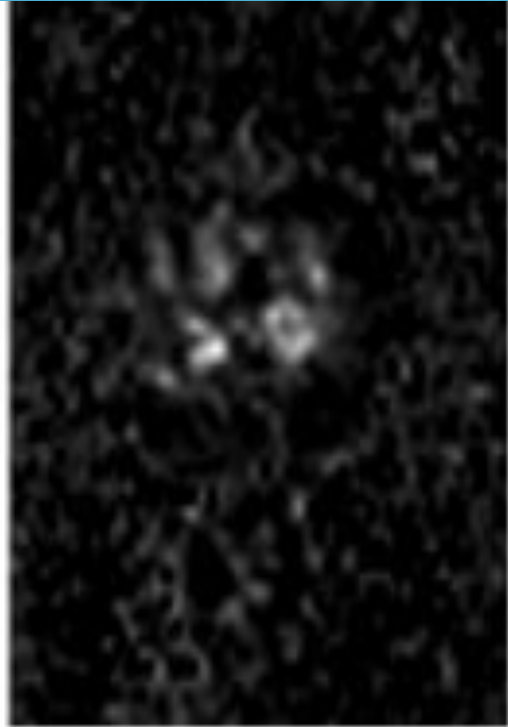
1



No abnormality (i.e. normal) on ADC and high b-value DWI.

PI-RADS ASSESSMENT FOR PERIPHERAL ZONE ON DWI

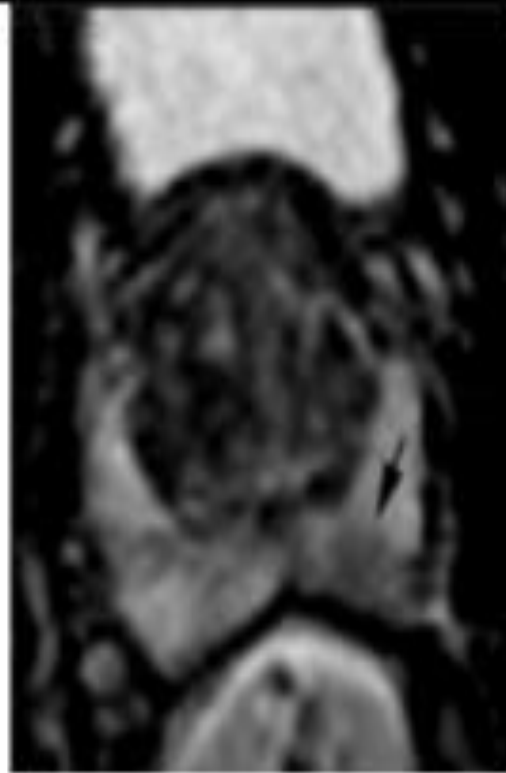
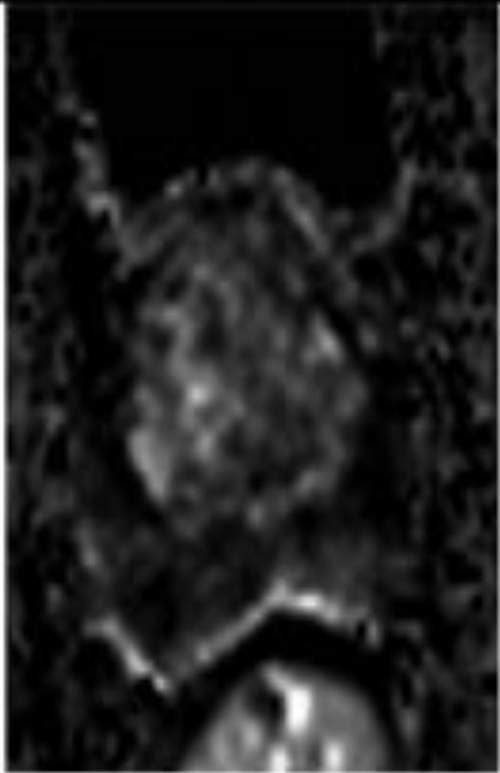
2



Indistinct hypointense on ADC (*arrow*).

PI-RADS ASSESSMENT FOR PERIPHERAL ZONE ON DWI

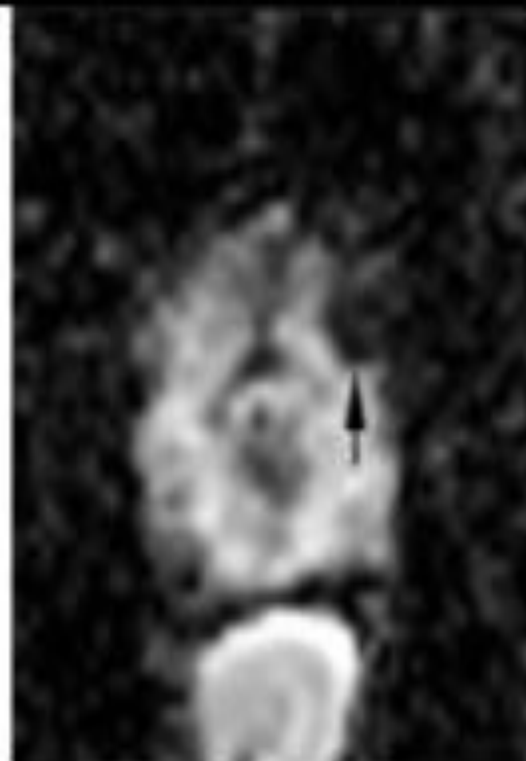
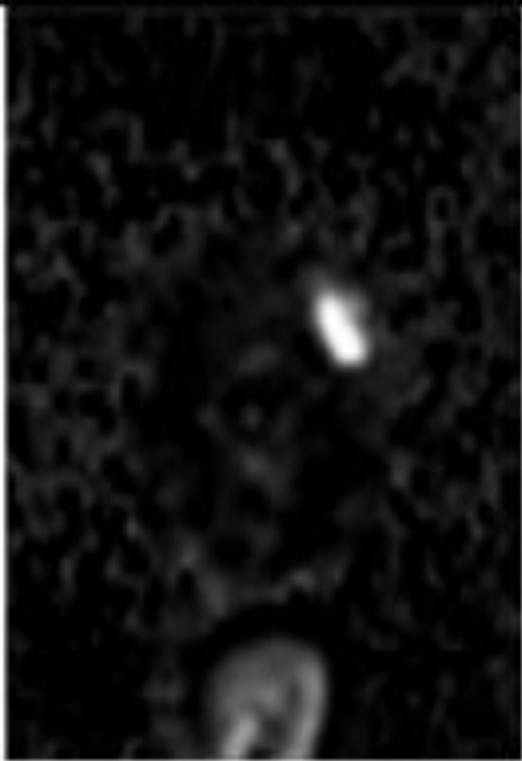
3



Focal mildly/moderately hypointense on ADC (*arrow*) and isointense/mildly hyperintense on high b-value DWI.

PI-RADS ASSESSMENT FOR PERIPHERAL ZONE ON DWI

4

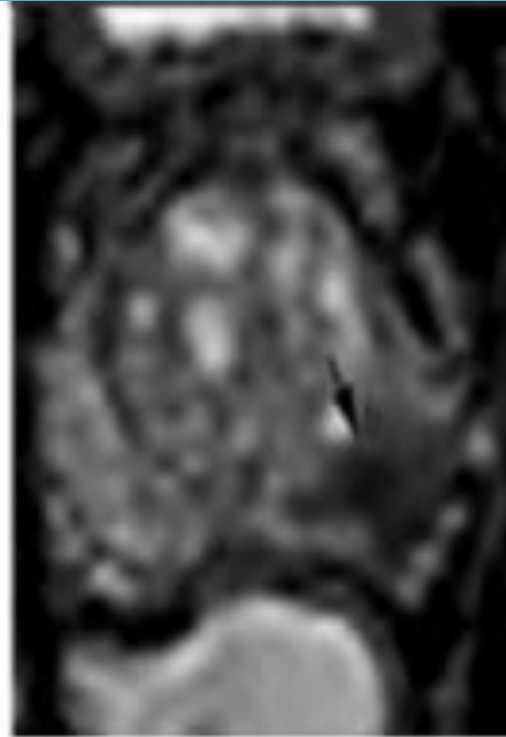
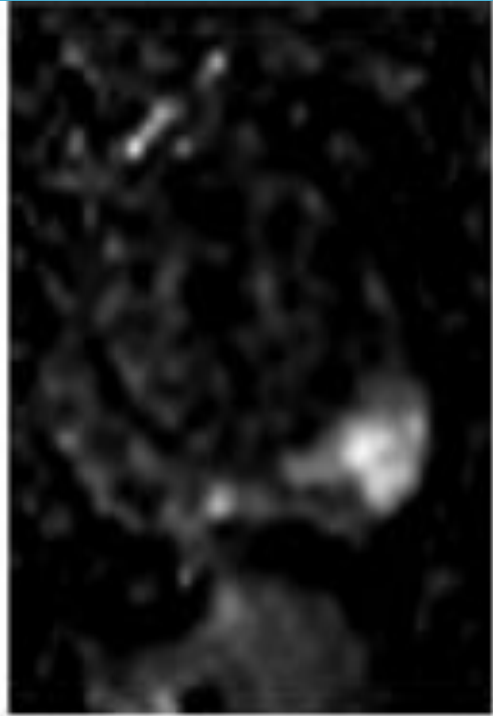


Focal markedly hypointense on ADC (*arrow*) and markedly hyperintense on high b-value DWI;

<1.5cm on axial images.

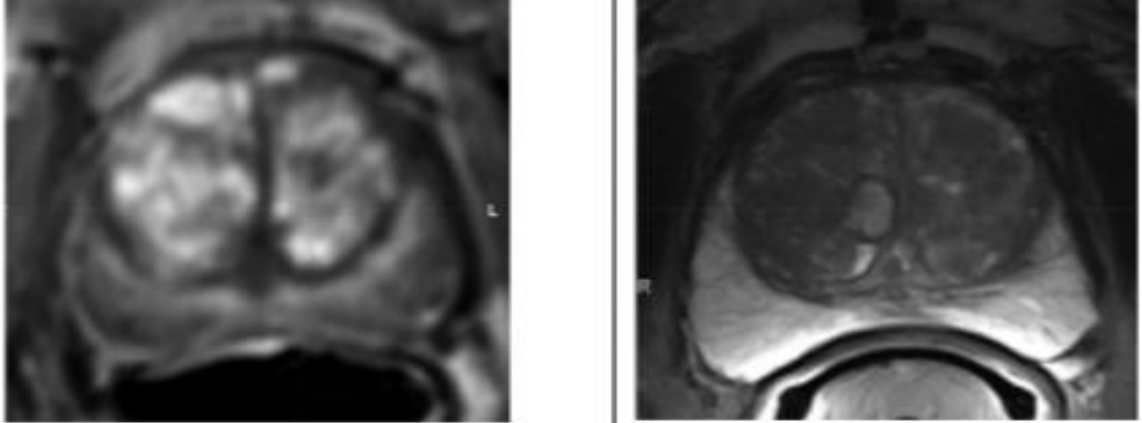
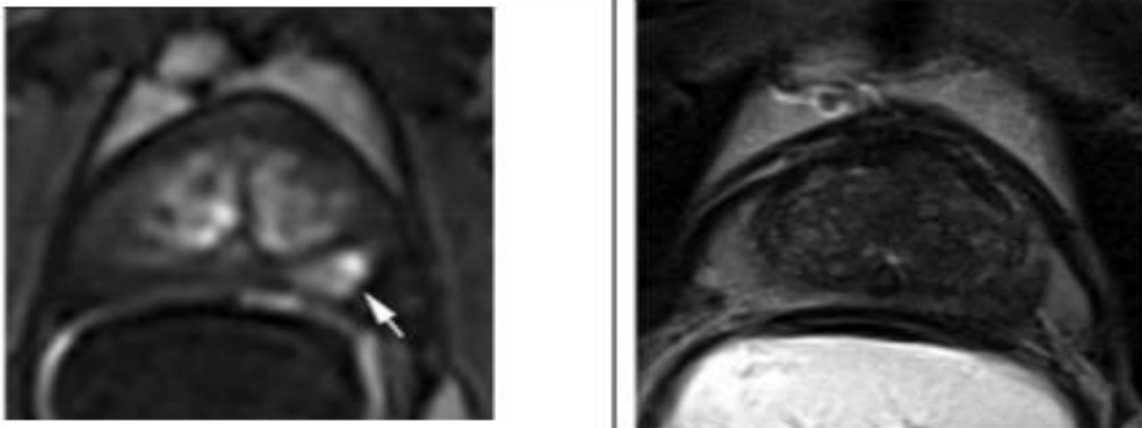
PI-RADS ASSESSMENT FOR PERIPHERAL ZONE ON DWI

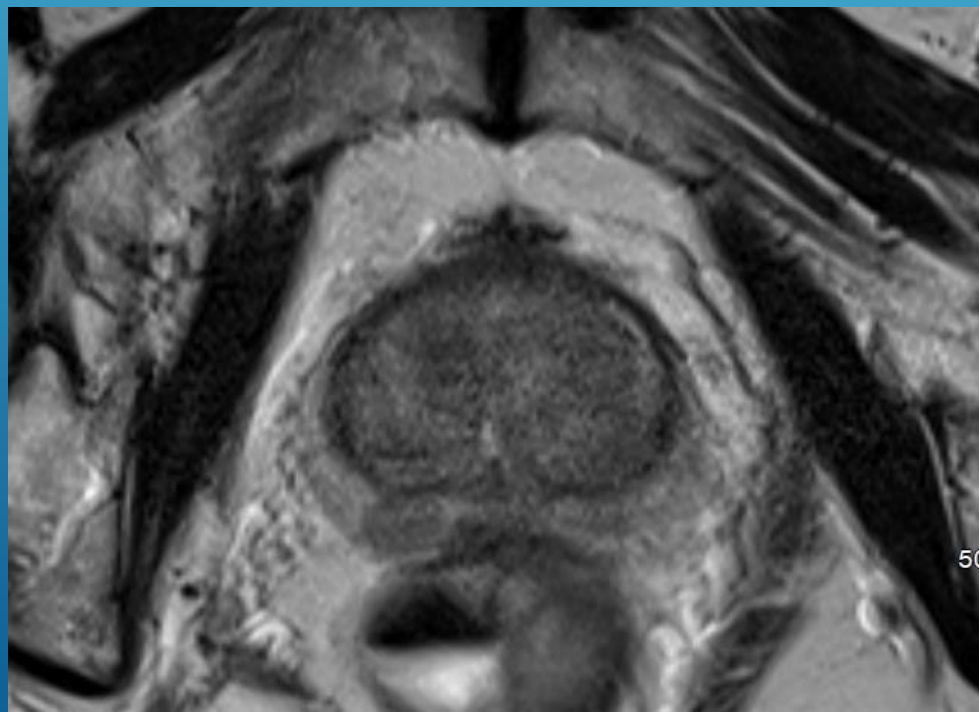
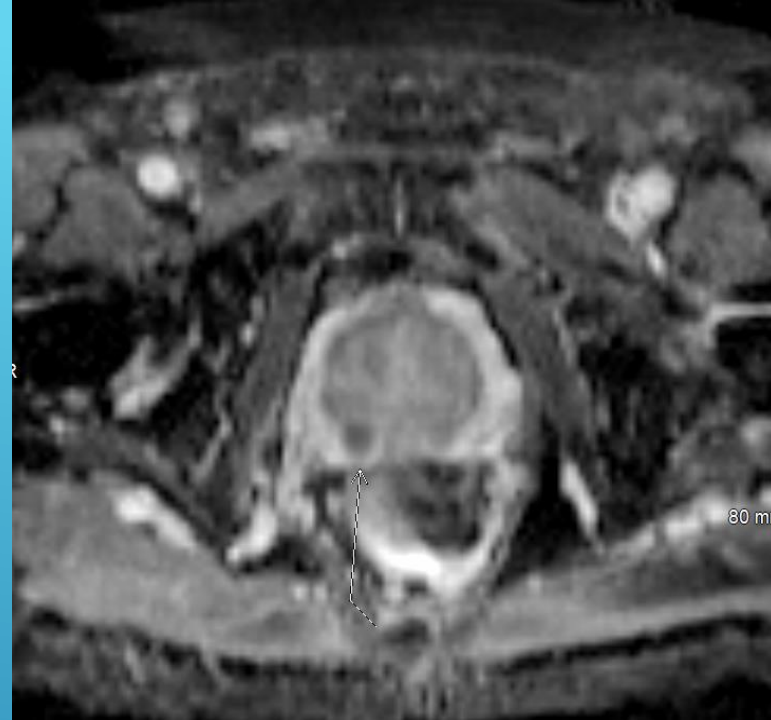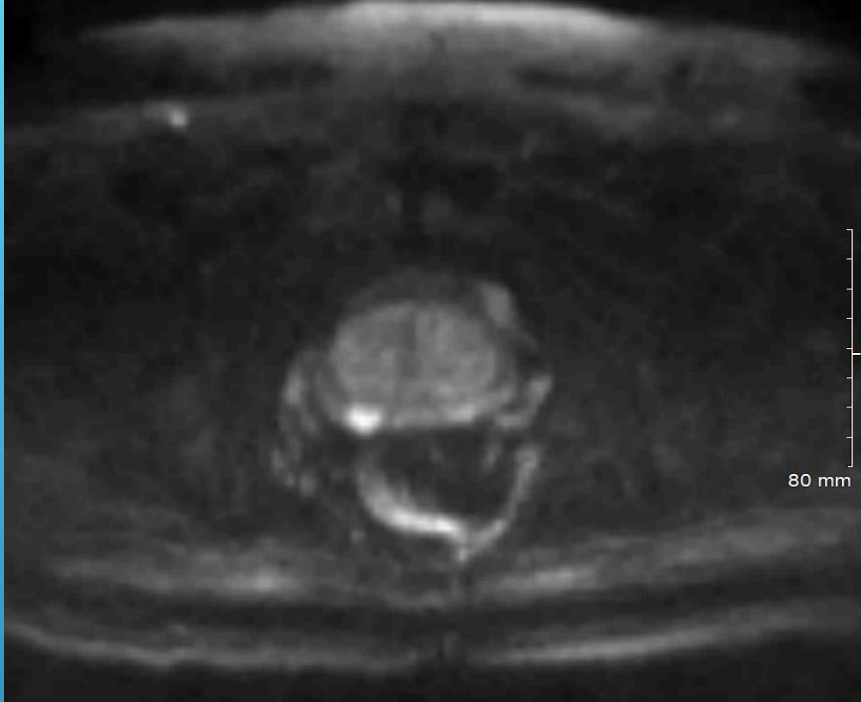
5

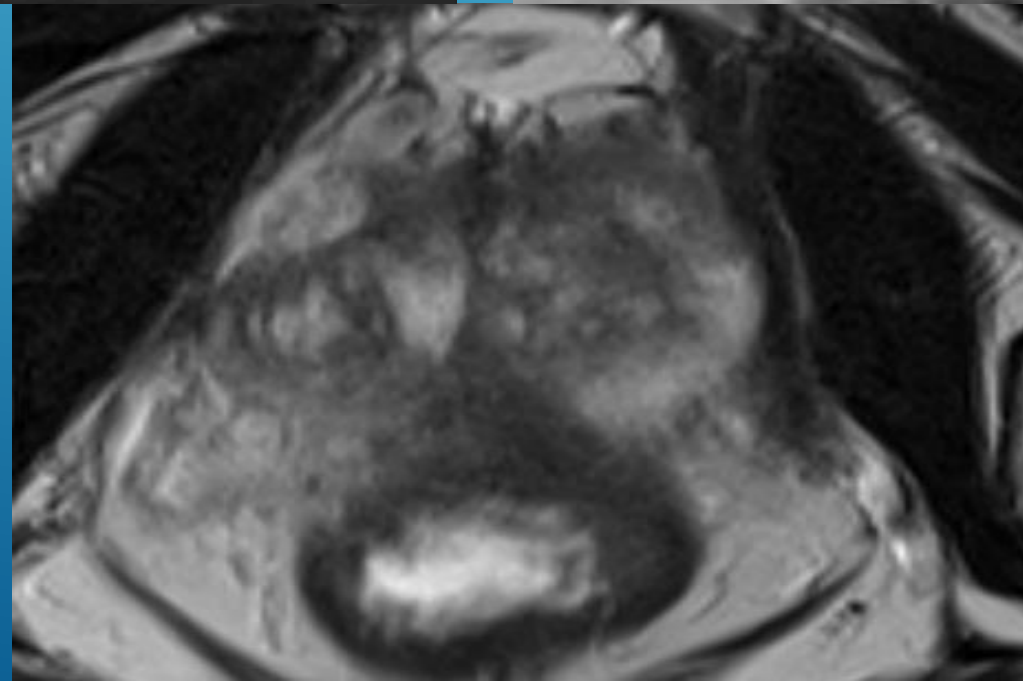
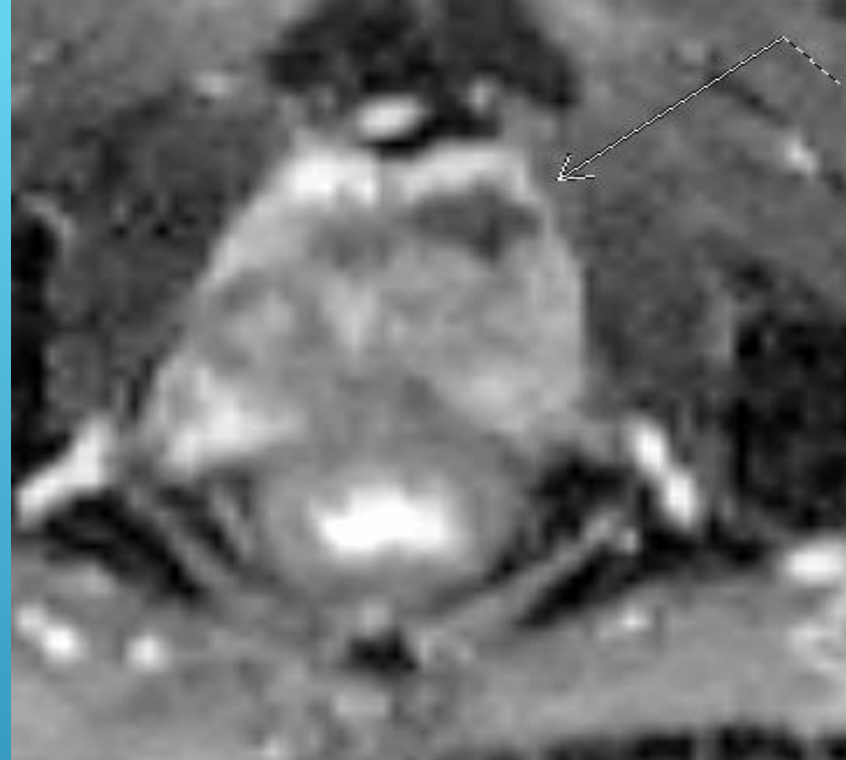
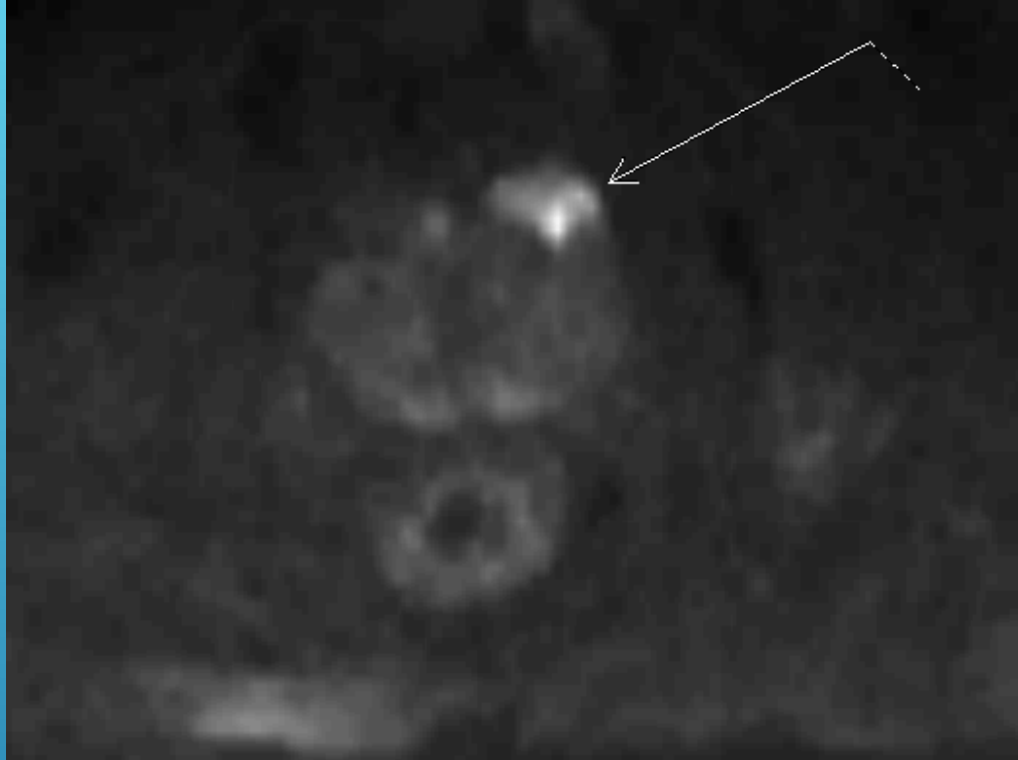
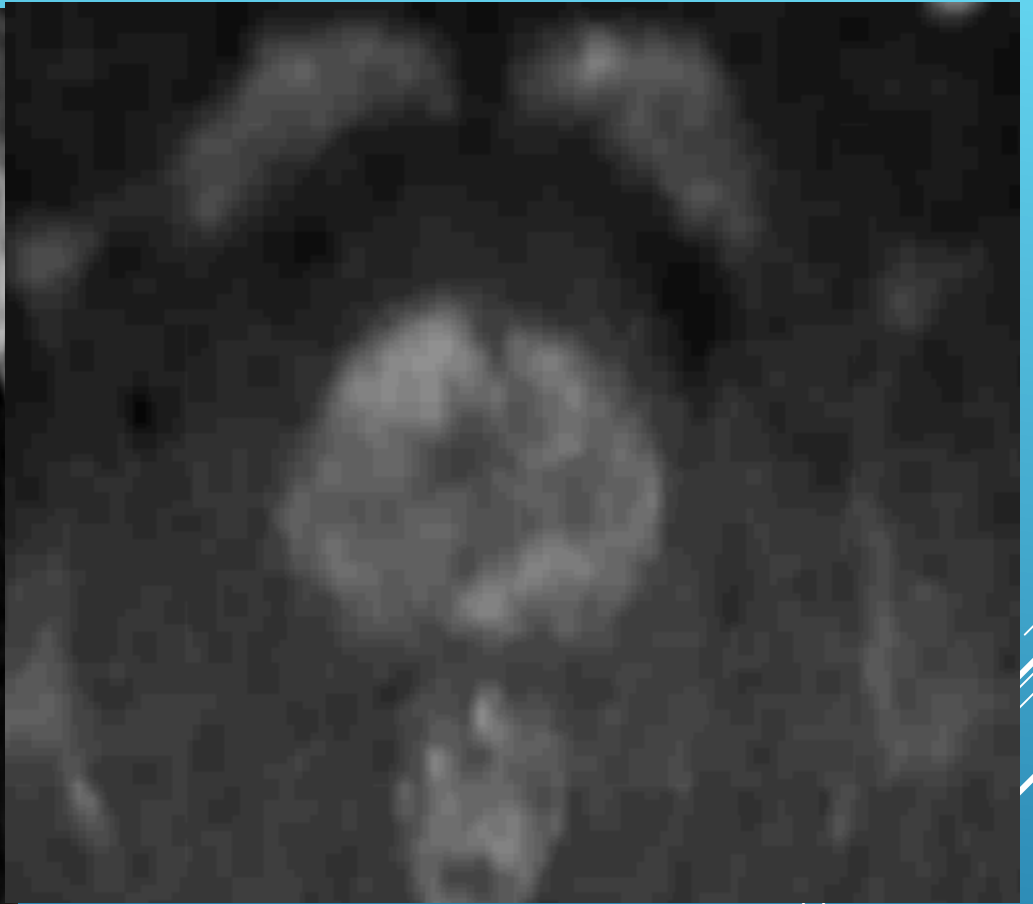
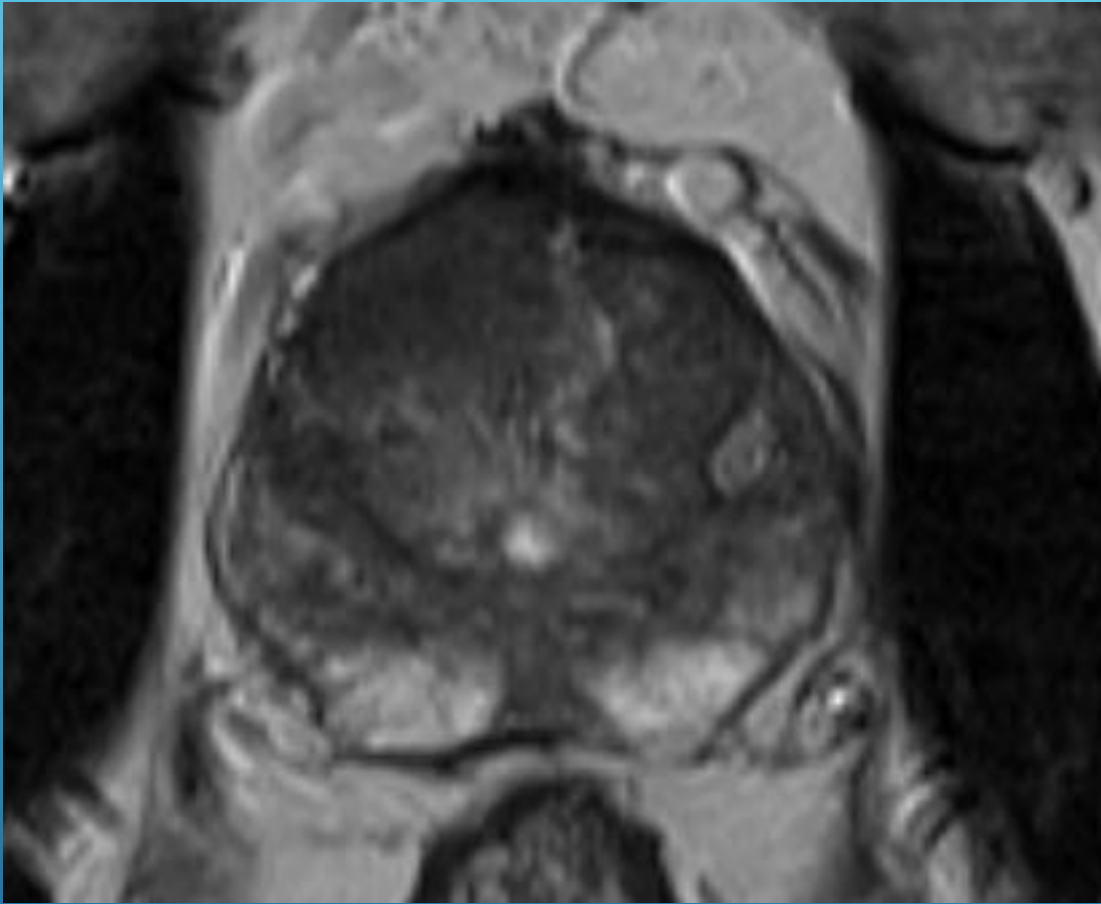
Same as 4 but ≥ 1.5 cm in greatest dimension (*arrow*) or definite extraprostatic extension / invasive behavior.

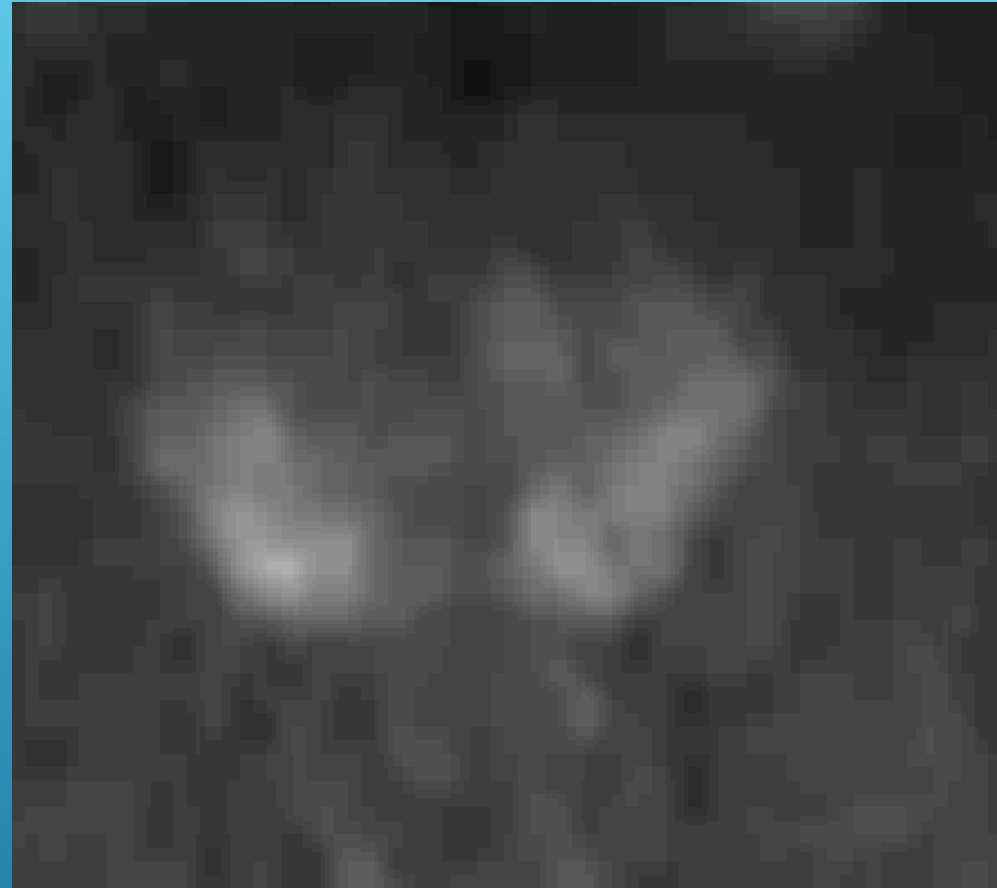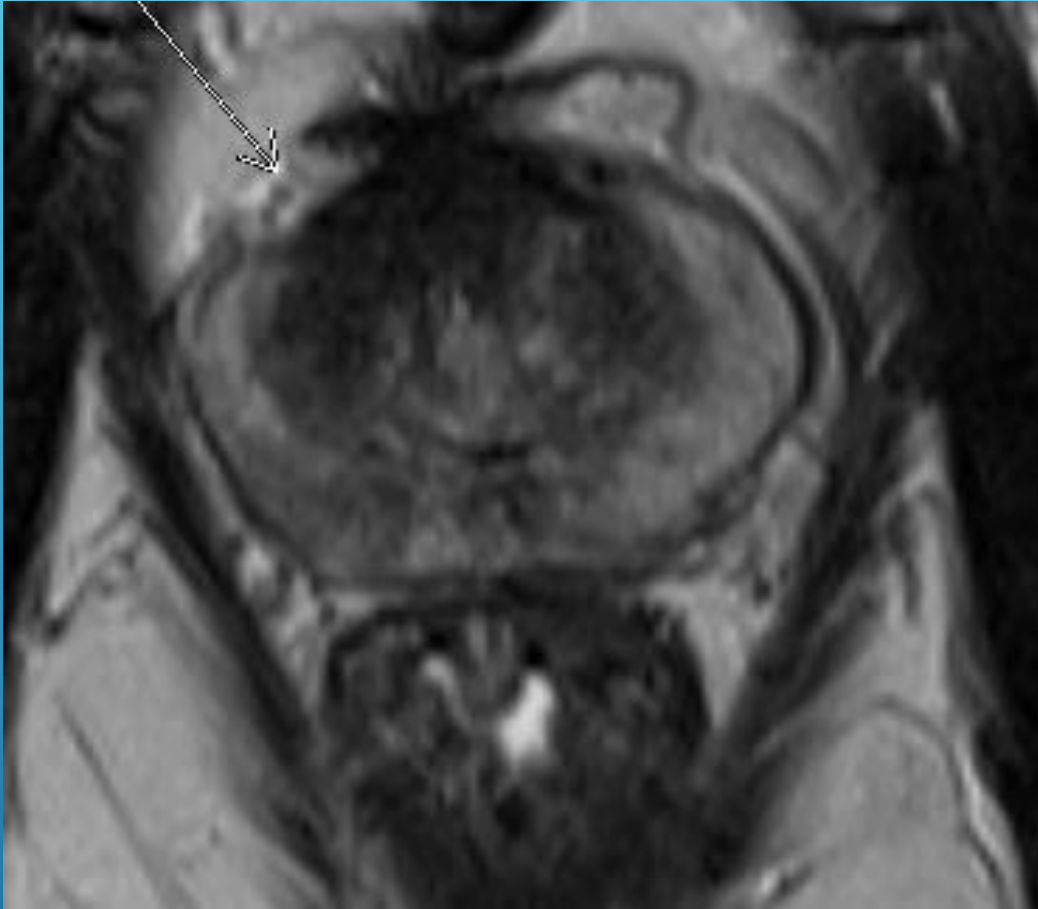Figure 7 – PI-RADS assessment for dynamic contrast enhanced MRI.

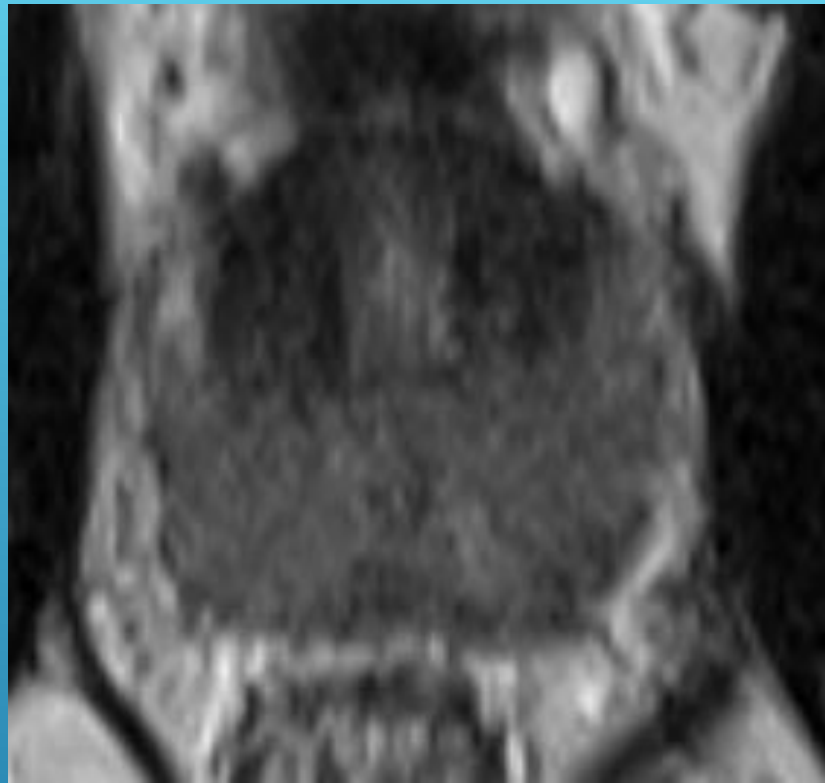
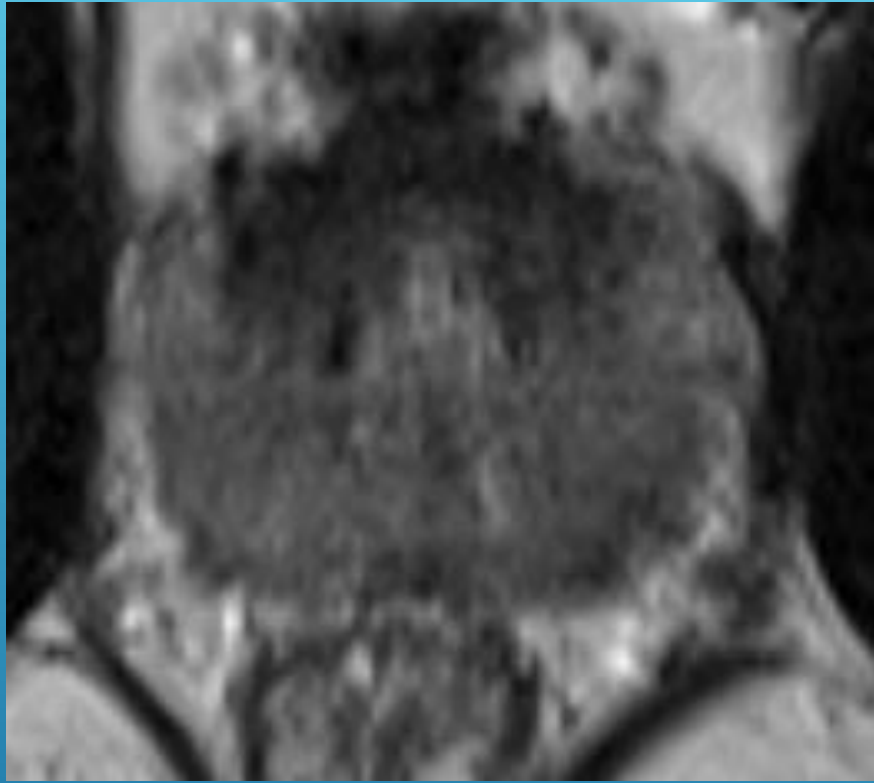
Negative	<p>No early enhancement, or; diffuse enhancement not corresponding to a focal finding on T2WI and/or DWI, or; focal enhancement corresponding to a lesion demonstrating features of BPH on T2W</p>
	
Positive	<p>Focal (<i>arrow</i>), and; earlier than or contemporaneously with enhancement of adjacent normal prostatic tissues, and; corresponds to suspicious finding on T2WI and/or DWI</p>
Peripheral Zone	






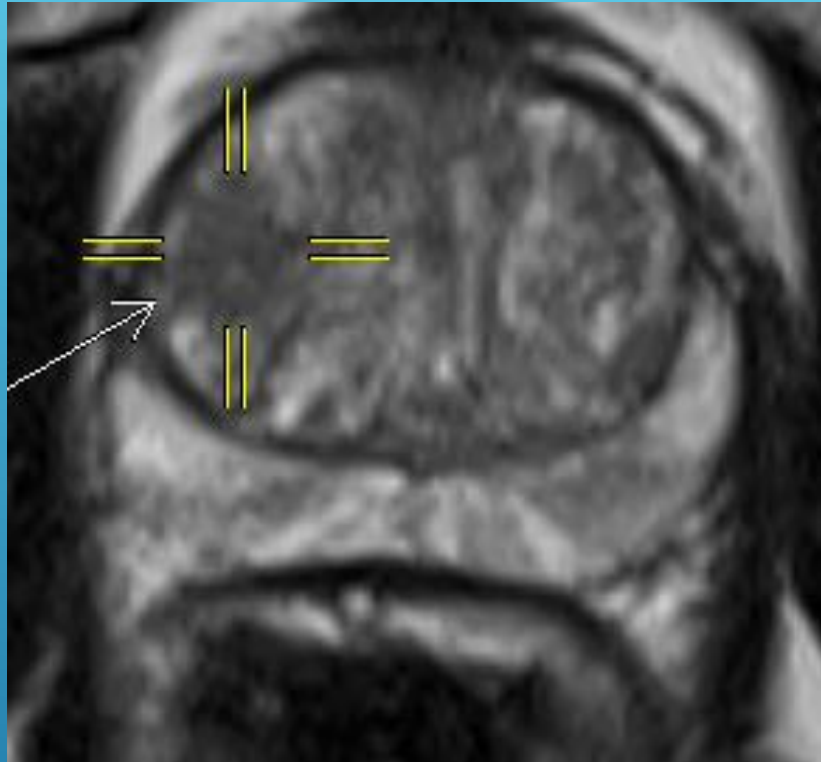








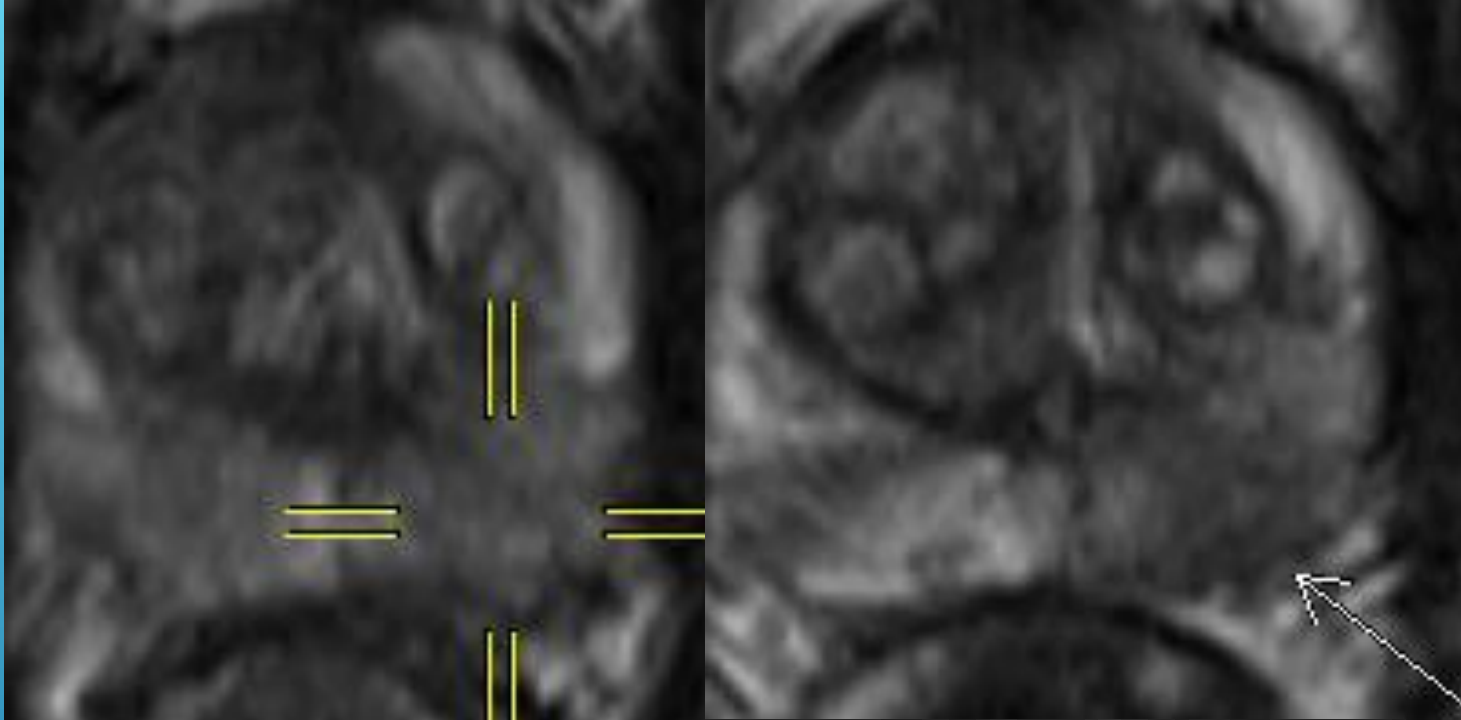
IS THIS AN ANTERIOR TZ CANCER?

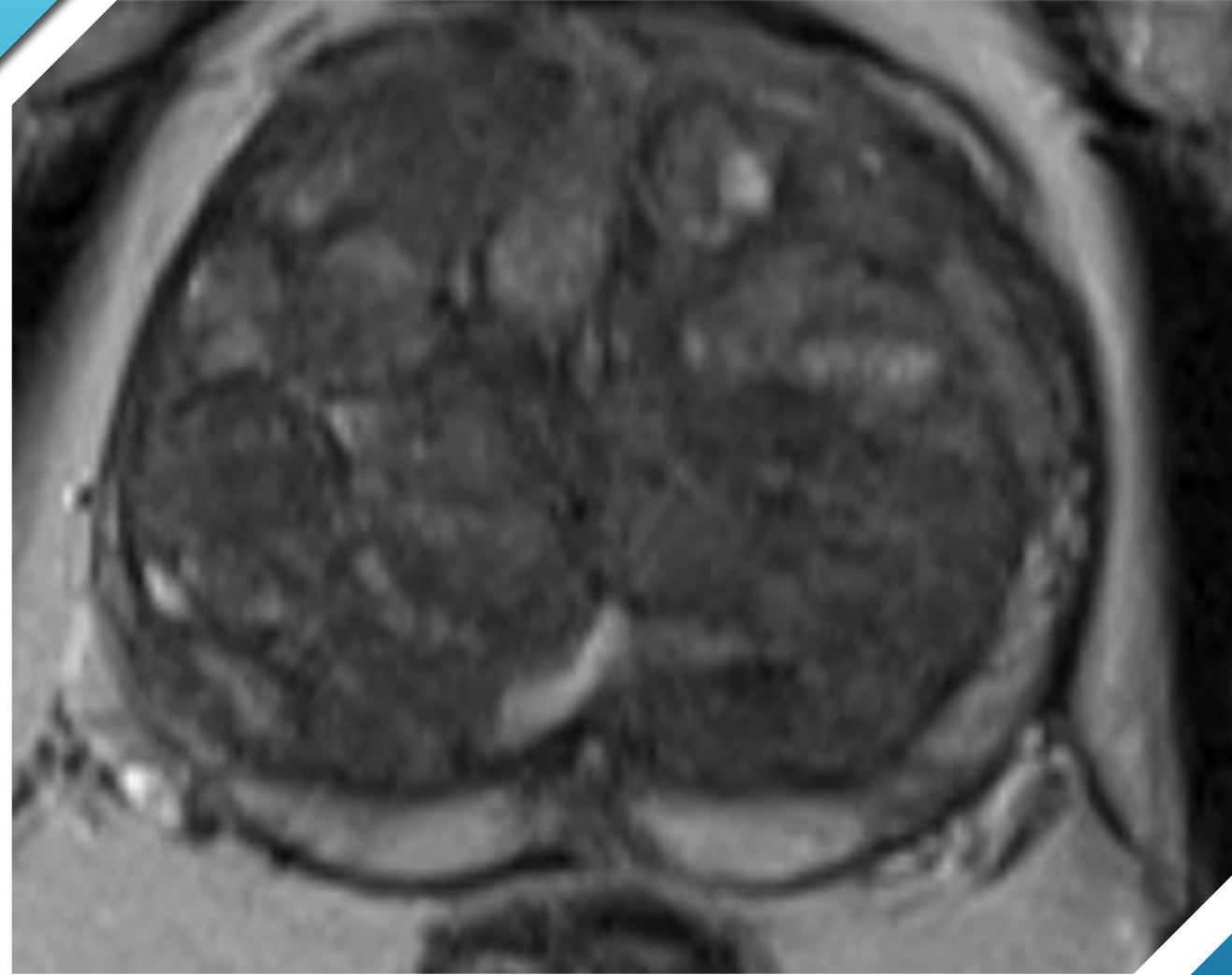




STILL A PIRADS 3?







IS THIS
PIRADS 2 OR
3?

CONCLUDING THOUGHTS:

- prostate MRI in the setting of elevated PSA in a biopsy naïve patient remains controversial and not currently accepted indication in Ontario
- PI-RADS version 2 standardizes prostate MRI image acquisition, interpretation, and reporting
- DWI is the dominant sequence in peripheral zone
- T2 is dominant sequence in transitional zone
- challenges remain in prostate MRI interpretation, particularly in the transitional zone
- False negative rate of prostate MRI is 10-20% in all comers, likely mostly due to transitional zone heterogeneity and low tumour density prostate cancer

THANK YOU FOR YOUR
ATTENTION

A decorative graphic consisting of several parallel white lines of varying lengths, all slanted upwards from left to right, located in the bottom right quadrant of the slide.